

# Crown Considerations, Preparations, and Material Selection for Esthetic Metal-Ceramic Restorations

Edward A. McLaren, DDS

Greg Vigoren, DDS



**Edward A. McLaren, DDS**  
Director, Center for Esthetic  
Dentistry  
Director, School for Esthetic Dental  
Design  
School of Dentistry  
University of California at  
Los Angeles  
Los Angeles, California



**Greg Vigoren, DDS**  
Adjunct Faculty  
Center for Esthetic Dentistry  
School of Dentistry  
University of California at  
Los Angeles  
Los Angeles, California

Private Practice  
Newport Beach, California

## ABSTRACT

In recent years, many dentists and patients have opted for metal-free restorations amid concerns regarding esthetics and potential metal toxicity. The use of a Captek™ substrate with a new-generation, lower-fusing porcelain has demonstrated excellent esthetic results, proving that it is possible to fabricate porcelain-fused-to-metal restorations that rival any all-ceramic restoration. This article will discuss the clinical considerations in the use of crown systems, and preparation guidelines for esthetic metal-ceramic restorations using Captek™ cores.

## LEARNING OBJECTIVES

After reading this article, the reader should be able to:

- describe the preparation techniques for single- and multiple-crown situations.
- identify situations in which a core system should be used.
- discuss the clinical situations in which full-coverage crowns supported by a high-strength core should be considered.
- explain the difficulties in controlling proper tooth reduction in clinical situations where multiple crowns are necessary.

Esthetic metal ceramics have seemed almost oxymoronic to many dentists and patients. The esthetic push in recent years has been for the metal-free restoration under the guise that superior esthetics can be obtained only without using metal substrates in crown restorations. Also, concerns over potential metal toxicity have led the public and many dentists to choose metal-free restorations. Many of these metal-free systems, marketed as alternatives to

conventional porcelain-fused-to-metal (PFM) restorations, have little or no clinical or toxicity data to support their use. High-gold alloys have proven safe and are tolerated well by patients; it has been only the use of nonprecious alloys that have created toxic reactions in patients.<sup>1</sup> Porcelains have proven to be highly biocompatible, which favors a healthy gingival response, and are frequently used in restorations for veneers, metal-ceramic, or high-strength ceramic copings.<sup>2</sup>

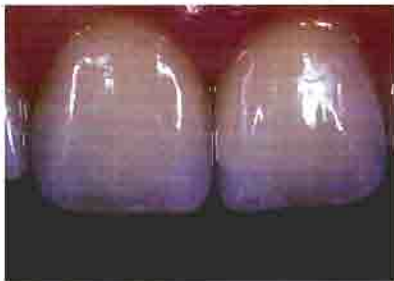However, it is possible to fabricate PFM restorations that rival any all-ceramic restoration esthetically<sup>3</sup> with the proper use of new-generation porcelains and alloy systems.<sup>4</sup> Specifically, the use of a Captek™ substrate with Vita® Omega 900®, a new-generation, lower-fusing porcelain, has demonstrated excellent esthetic results (Figure 1). The specific framework design parameters for the esthetic fabrication of porcelain-veneered Captek™ crowns is dealt with elsewhere.<sup>1,5</sup> As critical as the design parameters are for the restoration to obtain an esthetic result, also critical is the proper tooth preparation to allow room for the esthetic material.

## CROWN CONSIDERATIONS

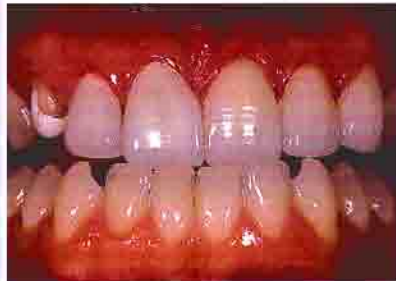Ideally, the least amount of tooth structure possible should be removed when preparing teeth for crown restorations. In situations where minimal tooth structure removal is required, a porcelain-bonded restoration is indicated, assuming it will satisfy the functional and esthetic requirements of the patient (Figures 2 and 3).<sup>6</sup> Excess tooth structure should never be mutilated to satisfy the requirements of a certain material when a more conservative approach will satisfy functional, biologic, and esthetic requirements. Clinical situations that require a conventional PFM are the same for a Captek™-supported restoration.

Captek, Altamonte Springs, FL 32714; 800-921-2227

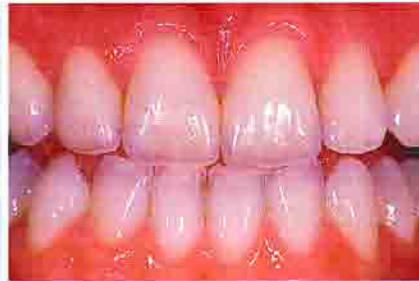Vita Zahnfabrik, Germany distributed in US by Vident™, Brea, CA 92621; 800-848-2726



**Figure 1**—Porcelain-fused-to-gold crowns on teeth Nos. 8 and 9 fabricated with a Captek™ substrate and Vita® Omega 900, a new-generation, lower-fusing porcelain.



**Figure 2**—Preoperative condition where the structural integrity of the remaining tooth was ideal for bonded porcelain.



**Figure 3**—Postoperative view of bonded porcelain veneers on teeth Nos. 8 and 9. Note the esthetic integration of these very conservative, bonded porcelain restorations.

Full-coverage crowns supported by a high-strength core should be considered in the following clinical situations: to replace an existing PFM restoration; when there is a compromised substrate (tooth); and when there is need for support for the porcelain. It is important to understand that porcelain gets its strength from being bonded to a high-strength substrate—either enamel, metal, or ceramic core. If the substrate has only dentin or composite—both of which are low modulus (flexible) materials—then the less flexible and more brittle ceramic will absorb a disproportionate amount of stress under load, which increases the chance for brittle failure.<sup>7</sup> In a study that looked at the failure load of bonded, pressed ceramics to materials of different elastic moduli, it was concluded that the failure load was proportional to the flexibility of the substrate.<sup>8</sup> The more flexible the substrate, the lower the failure load. Thus, thin teeth or extremely broken-down teeth, especially those with a large (and flexible) composite buildup, should not be considered for bonded porcelain restorations that have no core support. In these clinical situations, a crown should be placed that uses a high-strength core.

A core system should also be used in situations where porcelain would be subjected to high shear and tensile stresses. Porcelain can

extend several millimeters occlusally or incisally in situations where the stresses placed on it will be primarily compressive in nature and the substrate is stiff.

**It is possible to fabricate PFM restorations that rival any all-ceramic restoration esthetically with the proper use of new-generation porcelains and alloy systems.**

## PREPARATIONS

The correct reduction for the room necessary for the esthetic fabrication of a Captek™ or, for that matter, any PFM restoration is paramount. Evaluation of more than 700 Captek™ restorations in which the primary author performed all clinical and ceramic procedures has led to the determination that 1.2 mm of overall labial crown thickness was the minimum ideal dimension for predictable esthetics. All of those 700-plus restorations were documented and measured for final crown dimensions before cementation, and subjective analysis was made as to the esthetic success of the cemented restorations. It was determined

that a 1.2-mm facial crown dimension allowed predictable shape reproduction and subjective esthetic success. Thus, it is recommended to reduce facially to allow for a final restoration with a facial dimension of 1.2 mm. This may not mean that 1.2 mm of tooth structure needs to be removed facially. Esthetic and functional requirements will dictate whether more or less tooth should be removed, because labializing or lingualizing the facial surface may need to be accomplished. The correct reduction for a single crown is fairly easy, but the correct reduction for multiple-crown situations is much more complex.

## SINGLE-CROWN SITUATIONS

Reduction for single crowns is generally dictated by the adjacent teeth, which is easy to visualize and compare. It is sometimes necessary to build up the tooth to the desired final shape before initiating the preparation process to better visualize the correct amount of reduction necessary for the final restoration. Before crown preparation, caries and old restoration removal with concomitant foundation restoration placement should be accomplished.

Small carious lesions or old restorations can be removed during the gross reduction steps of the crown preparation. Figure 4 dem-

onstrates the UCLA Center for Esthetic Dentistry Metal-Ceramic and All-Ceramic Preparation Kit (338.31.620) by Dr. McLaren<sup>®</sup>. The first step in the process is to break contact with the adjacent teeth (Figure 5) using the coarse diamond (#5858-014<sup>°</sup>). The marginal area is prepared next with either a KS1<sup>°</sup> or KS2<sup>°</sup> diamond (Figures 6A and 6B). The marginal preparation is done right to the level of the gingiva (Figure 7). The marginal area is the most critical area when preparing for a PFM with a porcelain margin or an all-ceramic crown, and experience has shown that a 360-degree, 1-mm shoulder preparation with a 90-degree exit angle and rounded internal line angles is ideal for these restorations (Figure 8).

<sup>°</sup>Brasseler USA<sup>®</sup>, Savannah, GA 31419; 800-841-4522

All other areas of the preparation can be altered on the worked die by the ceramist if necessary to create more room, and can subsequently be adjusted intraorally by the dentist. An underprepared

**A**n underprepared marginal area is impossible to compensate for in the laboratory.

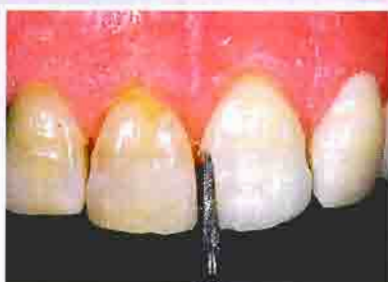marginal area is impossible to compensate for in the laboratory and would require repreparation and reimpresioning, hence the rationale for preparing the margin early in the preparation process.

Axial reduction is next, and

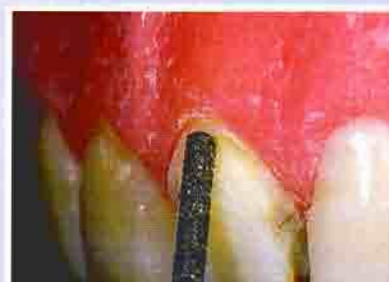can be controlled by a number of techniques. Classically, it is recommended to use depth cuts to gauge the amount of reduction. This technique works only if the amount of tooth structure removal is the same as the amount of tooth structure that will be replaced. It does not work if the labial position of the tooth is being altered in the final restoration. Depth grooves generally allow the correct reduction in single-crown situations where the final restoration will follow the contour of adjacent teeth. Depth grooves are placed with a KS1, KS2, or KS3<sup>°</sup> diamond (Figure 9) depending on the necessary reduction. The same diamond used for the depth cuts is used to remove the remaining tooth structure to the desired depth (Figure 10). The goal for a Captek<sup>™</sup>



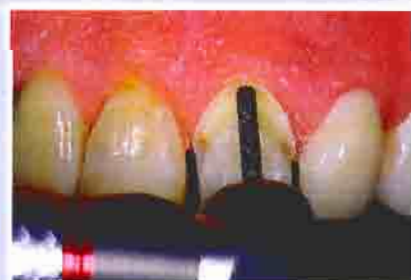**Figure 4**—The UCLA Center for Esthetic Dentistry Metal-Ceramic and All-Ceramic Preparation Kit by Dr. McLaren.



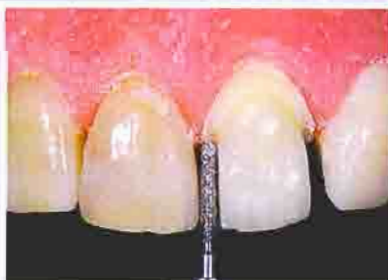**Figure 5**—Breaking contact with the #5858-014 diamond on a demonstration model in which natural teeth are mounted.



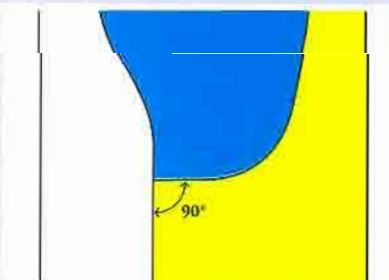
**Figure 6A**—Profile view of initial margin placement done with either the KS1 or KS2 diamond.



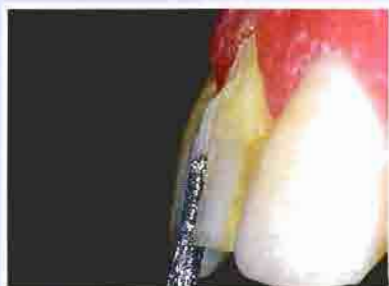**Figure 6B**—Facial view of margin placement done with either the KS1 or KS2 diamond.



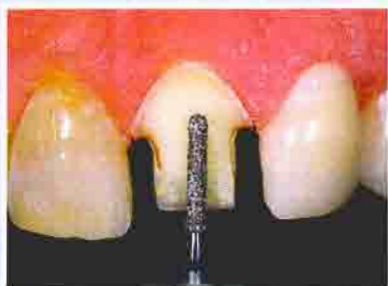**Figure 7**—Initial margin placement is done right to the level of the gingiva facially and interproximally. Interproximally, a KS1 is used so as not to damage adjacent teeth.



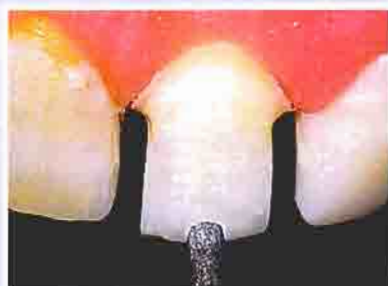**Figure 8**—Shoulder margin with rounded axial-gingival line angle.



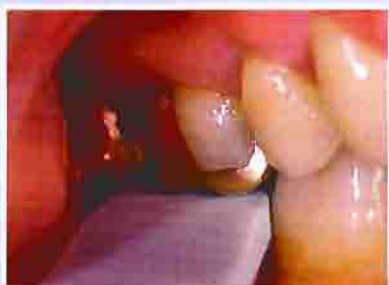**Figure 9**—Depth grooves are placed with either a KS1 or KS2 diamond.



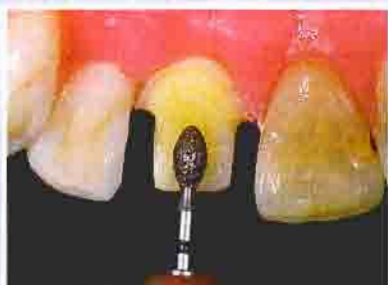**Figure 10**—Axial reduction is completed using the same KS diamond used for the depth cuts.



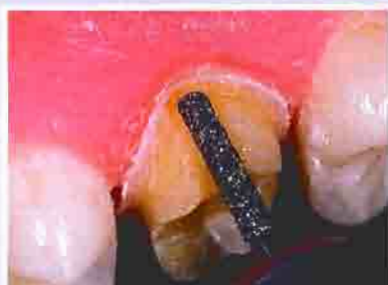**Figure 11**—Incisal edge reduction using the KS3 diamond.



**Figure 12**—Using the 2-mm Reduction Guide to check the occlusal reduction on tooth No. 30.



**Figure 13**—Lingual reduction is accomplished on anterior teeth with the egg-shaped KS4-024 diamond.



**Figure 14**—Lingual reduction for posterior teeth is done with a KS2 or KS3 diamond.

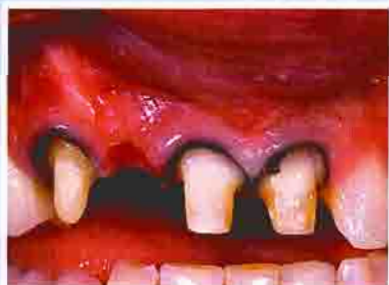restoration should be to allow for 1.2 mm of space labially. Incisal or occlusal reduction is initiated with a KS3 diamond. Incisal edge reduction of 2 mm is adequate for good esthetics. The diameter of the KS3 is 1.6 mm, so going slightly deeper gives the necessary 2-mm reduction (Figure 11). The adjacent incisal edge can also be gauged as

a reduction guide. Posteriorly, it is necessary to have 2.5 mm of occlusal reduction for both esthetic metal-ceramic and all-ceramic restorations, especially if natural, unworn occlusal anatomy is desired in the final restoration. The best aid the authors have found to accomplish this reduc-

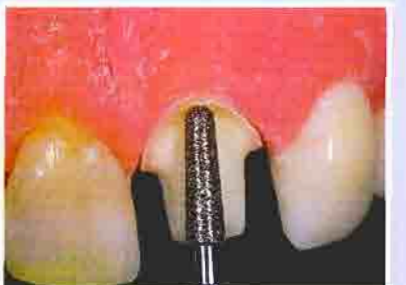\*KerrLab, Orange, CA 92867; 800-537-7123

tion is the 2-mm Reduction Guide<sup>d</sup>. If the 2-mm guide passes with only slight binding through the occluded opposing arches, then there is close to 2.5 mm of interocclusal space (Figure 12). Lingual reduction is done with the KS4-024<sup>e</sup> diamond for anterior teeth (Figure 13) and a KS2 or KS3 for posterior teeth (Figure 14) to allow for at least 0.7 mm of crown thickness for anterior teeth and 1.0 mm thickness for posterior teeth.

Before finishing the preparation, one layer of Ultrapack<sup>®</sup> #000<sup>®</sup> is placed in the sulcus (Figure 15). This generally gives 0.5 mm of gingival displacement. The margin is apically positioned 0.5 mm with either a KS1 or KS2 (Figure 16) diamond or, in cases with excessively scalloped gingival margins, the KS6<sup>®</sup>. The depth to which the margin should be placed in the sulcus is a complex issue and affect-

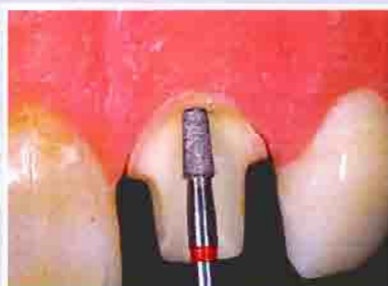

**Figure 15**—A clinical case with Ultrapack<sup>®</sup> #000 cord placed to obtain initial gingival retraction so that the margins can be finished. The margin was prepared to the level of the retraction cord.

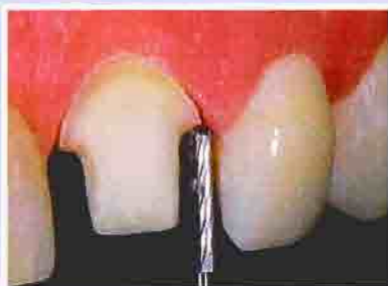

**Figure 16**—The apical position of the margin is placed with either a KS1, KS2, or, as shown, a KS6 diamond.

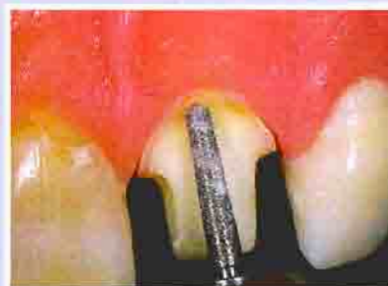<sup>d</sup>Ultradent Products, Inc, South Jordan, UT 84095; 800-552-5512



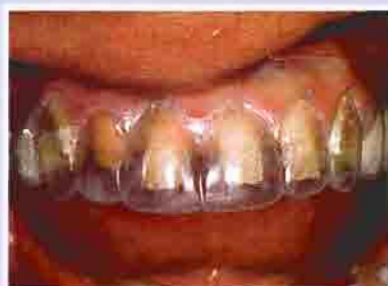**Figure 17**—Final margin finishing is completed with either the #8845KR-018 or #8845KR-025 fine diamond.



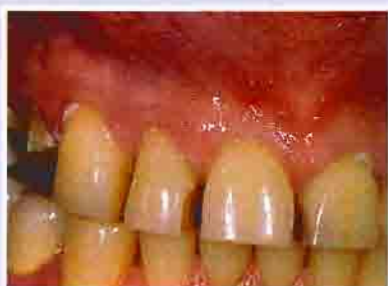**Figure 18**—The finishing carbide bur H158-014 can also be used to finish the margin.



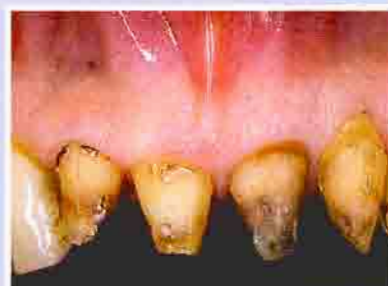**Figure 19**—Axial contours are finished with either the #8881-014 or #8856L-020 fine diamond.



**Figure 20**—Using a polypropylene matrix to gauge gross reduction.



**Figure 21**—A clinical case in which all maxillary teeth are to receive all-ceramic crowns. In these situations where adjacent teeth are prepared, the contact is broken using either the KS1 or KS2 diamond.



**Figure 22A**—Rough preparations immediately after old restoration removal.

ed by many variables.<sup>6,10</sup> The ultimate goal of margin placement is to have an esthetic restoration/gingival interface without biologic complications (ie, violation of biologic width). The marginal area is then finished with either the #8845KR-018° or #8845KR-025° finishing diamonds, or the H158-014° carbide finishing bur (Figures 17 and 18). Axial contours are finished with the #8881-014° or #8856L-020° fine diamonds (Figure 19). For all-ceramic crowns, it is critical to round all internal line angles with one of the fine diamonds. This minimizes stress concentrations in the ceramic crown by eliminating sharp angles.

## PREPARATIONS FOR MULTIPLE CROWNS

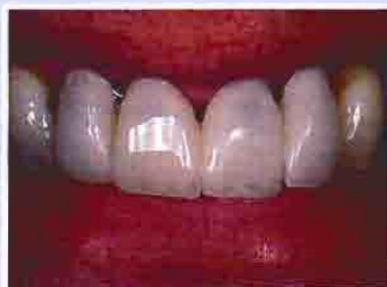Clinical situations in which multiple crowns are necessary

present extreme difficulties in controlling proper tooth reduction. Often, old crowns are being removed or the three-dimensional shape of the tooth is going to be altered significantly. In these situa-

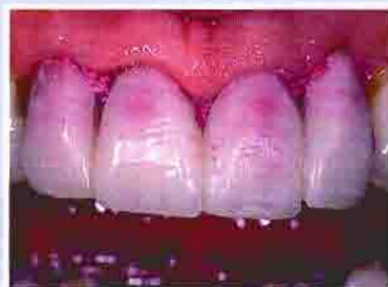**T**he depth to which the margin should be placed in the sulcus is a complex issue and affected by many variables.

tions, axial depth grooves are of limited value. It has generally been recommended to make a polypropylene vacuum-formed matrix to be used intraorally to control tooth reduction (Figure 20). While this is a useful adjunct, it is fraught

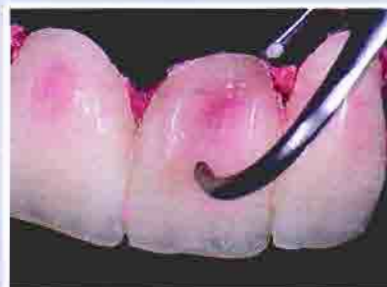with potential problems. When placed over the teeth, it is difficult to judge if the changes in tooth form that are incorporated into the matrix are in fact correct esthetically and functionally. Also, it is easy to displace the matrix in one direction or another up to almost 1 mm without knowing it. All of the above conditions could easily lead to overprepared or underprepared teeth. McLean described a technique where the prototype (temporary) is completed on the prepared teeth and then measured with a caliper to gauge proper tooth reduction.<sup>11</sup> Although this is the best method, two or three relines may be necessary to finalize the reduction amount, which is not very practical. One problem with this technique is that acrylic monomers left on the prepared tooth will inhibit the set of



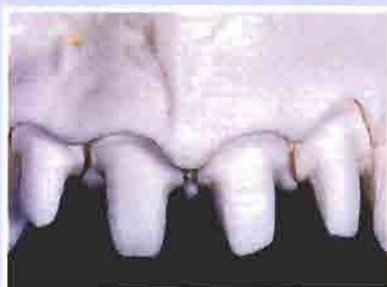**Figure 22B**—A shell prototype is tried over the rough prepared teeth to assess esthetic and functional acceptance of the desired anatomical changes.



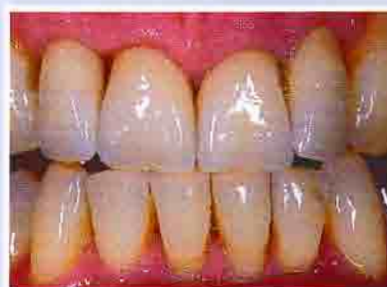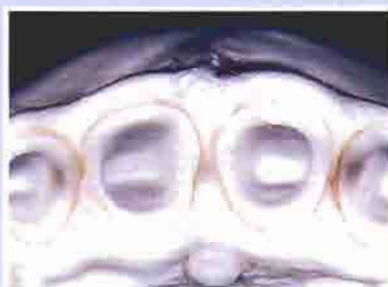**Figure 23A**—The shell prototype is altered as necessary for esthetics and function. The prototype is then relined with a fast-set PVS bite registration material.



**Figure 23B**—The prototype is measured for optimal thickness, and appropriate adjustments are made to the preparation to obtain the ideal reduction.



**Figures 24A and 24B**—Two views of the final preparations on the master casts, demonstrating ideal reduction for Captek™ restorations.



**Figure 25A**—View of the seated, final Captek™ crowns.

polyvinyl siloxane (PVS) impression materials. Therefore, an alternative technique will be discussed to control axial reduction.

Preparations for multiple-crown situations begin by either removing the old crowns or breaking contact (Figures 21 and 22A). Contact is broken in the same manner as for a single crown, but larger diamonds can be used if the adjacent tooth is going to be prepared. The margins for all the teeth being prepared are placed second using either the KS1 or KS2 diamond. The margins are placed at this juncture following the same rationale as stated for single crowns. Gross axial reduction is done using the clear vacuum matrix as a guide, but should not be relied on for the final reduction for the reasons stated previously. Final reduction is accomplished using an alternative and very efficient technique that the authors

have used for years. After gross reduction, a preformed shell prototype made from the preoperative cast or a diagnostic wax-up is placed over the prepared teeth (Figure 22B). This prototype is then evaluated for esthetics and altered as necessary for esthetic

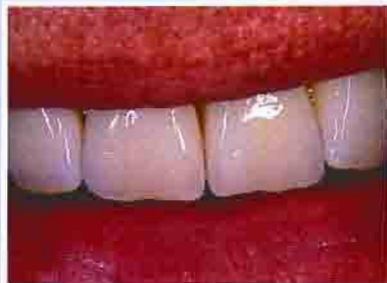### **C**linical situations in which multiple crowns are necessary present extreme difficulties in controlling proper tooth reduction.

acceptance. The prototype can then be relined with a fast-set PVS bite registration material (Figure 23A) and measured to verify reduction (Figure 23B). The tooth is then reduced as necessary with any of the KS diamonds. Another

benefit of this technique is that debris is cleaned off the prepared teeth before final impressioning. One layer of Ultrapack® #000 is then placed in the sulcus to obtain the initial tissue displacement. The final finishing steps and diamonds used are exactly the same as for single-crown situations (Figures 24A and 24B). Figures 25A through 25C represent a completed case of Captek™-supported PFM restorations using the preparation protocol presented in this article.

### **SUMMARY**

Many different criteria are involved in choosing the correct material or technique to treat a clinical situation. The authors presented a clinical rationale for choosing a crown system with a high-strength core of metal or ceramic vs an unsupported porcelain. Metal-ceramic restorations can rival all-ceramic restorations if



**Figure 25B**—View of the final Captex™ crowns. Note the esthetic match with the adjacent natural teeth.



**Figure 25C**—Full-face view of the same case. This is an excellent esthetic result for a patient in his late 60s.

the proper materials and design criteria are followed. Captex™ restorations require 1.2 mm of facial reduction for a predictable esthetic outcome, which is less than what is generally required for conventional metal-ceramics. Proper preparation techniques are of primary importance for esthetic success with metal-ceramic restorations.

*Authors' Note: All clinical and laboratory procedures were performed by Dr. McLaren.*

## REFERENCES

1. Schuster GS, LeFebvre CA, Watana JC, et al: Biocompatibility of posterior restorative materials. *J Calif Dent Assoc* 24(9):17-31, 1996.
2. 1990 Survey of Dental Restorations. In: *Survey of Dental Services 1990*. Chicago, ADA Survey Center, 1990.

3. Winter RR: Achieving esthetic ceramic restorations. *J Calif Dent Assoc* 18(9):21-24, 1990.
4. McLaren EA: Utilization of advanced metal-ceramic technology: clinical and laboratory procedures for a lower-fusing porcelain. *Pract Periodontics Aesthet Dent* 10(7):835-842, 1998.
5. McLaren EA: Forward to the past: a renaissance in ceramometal technology. *Contemp Esthet Rest Pract* 2(suppl 6):6-13, 1998.
6. Goldstein RE: Diagnostic dilemma: to bond, laminate or crown? *Int J Periodontics Restorative Dent* 7(5):8-29, 1987.
7. McLaren EA: All-ceramic alternatives to conventional metal-ceramic restorations. *Compend Contin Educ Dent* 19(3):307-326, 1998.
8. Scherrer SS, de Rijk WG: The fracture resistance of all-ceramic crowns on supporting structures with different elastic moduli. *Int J Prosthodont* 6(5):462-467, 1993.
9. Kois JC: Altering gingival levels: the restorative connection, part I: biologic variables. *J Esthet Dent* 6(1):3-9, 1994.
10. Kois JC: New paradigms for anterior tooth preparation: rationale and technique. *Contemp Esthet Dent* 2(1):1-8, 1996.
11. McLean JW: *The Science and Art of Dental Ceramics*. Chicago, Quintessence Publishing Co, pp 263-268, 1979.

Dental Learning Systems is an ADA Recognized Provider

Academy of General Dentistry Approved National Sponsor  
FAGD/MAGD Credit  
7/18/1990 to 12/31/2002