

THE SKELETON BUILDUP TECHNIQUE: A SYSTEMATIC APPROACH TO THE THREE-DIMENSIONAL CONTROL OF SHADE AND SHAPE

Edward A. McLaren, DDS*

Due to the limitations of current shade-matching systems, shade communication has proven inadequate. Techniques for the fabrication of porcelain crowns that match the natural dentition must address numerous factors. While all-ceramic restorations are indicated for the rehabilitation of the anterior dentition, these modalities are problematic in the restoration of teeth with discolored substrates. This article presents a systematic procedure for the three-dimensional fabrication of porcelain restorations. Techniques for building porcelain and altering the translucency of ceramic cores are also presented.

Patient demands for aesthetic, naturally appearing restorations are increasing exponentially, and the satisfaction of these objectives is a significant challenge for the restorative team. A plethora of new materials and techniques has been recently developed to facilitate this process.¹⁻⁴ The utilization of conventional metal-ceramic techniques is often incompatible with the development of aesthetic restorations in the limited space provided by traditional preparations. The size of the pulp and the need for conservation of tooth structure for structural integrity limit the degree of tooth reduction. The evolution of new alloy systems and aesthetic metal framework designs has enabled the restorative team to develop predictable, functional, and improved aesthetic results.^{5,6}

*Lecturer, Graduate Prosthodontics, UCLA School of Dentistry, Los Angeles, California; Adjunct Assistant Professor, University of Oregon School of Dentistry, Portland, Oregon.

Edward A. McLaren, DDS
32241 Crown Valley Parkway, Ste. 240
Monarch Beach, CA 92629

Tel: 714-488-2787
Fax: 714-493-2057

Recent advances in all-ceramic technology have expanded the alternatives for the aesthetic restoration of teeth.^{9,11} It is significantly easier to accomplish such restorations with an all-ceramic system that demonstrates optical properties (ie, value and translucency) similar to those of the natural dentition, which cannot be achieved with an opaque metal substrate. Consideration must be given not only to the manipulation of light, but also strength, improved handling properties, long-term clinical success, varied clinical applications, and biological compatibility. The In-Ceram system (Vident, Brea, CA) and its variations have satisfied these criteria in anterior and posterior single crowns.^{12,13} One possible limitation, however, has been identified as the second molar site, where space limits the maintenance of optimal core dimensions.¹⁴ In a clinical study conducted by Sorensen et al, anterior 3-unit fixed partial dentures fabricated of this all-ceramic material were 100% successful at 3 years, while exhibiting a significant failure rate for posterior fixed partial dentures.¹⁵

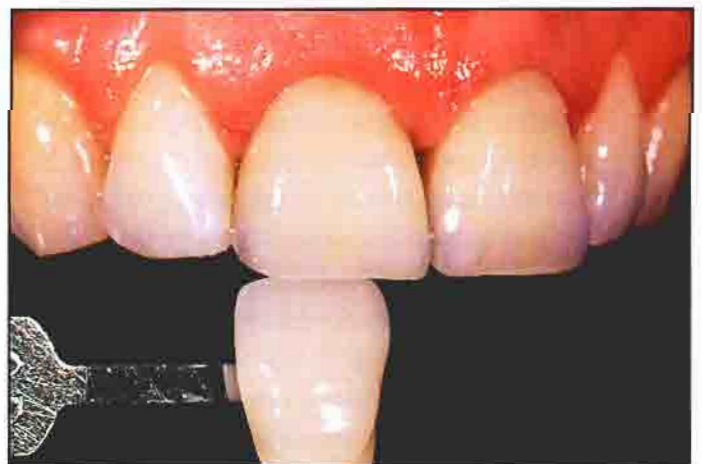

Figure 1. All-ceramic crown restorations, in situ with the shade guide, demonstrate an excellent match.

The results verified the manufacturer's recommendation to limit the use of this all-ceramic material to single crowns and anterior 3-unit bridges only.

The introduction of the advanced ceramic systems has occurred simultaneously with the development of sophisticated ceramic layering techniques.^{15,21} While ceramists are able to utilize these two elements to fabricate intricate restorations, the absence of the patient during the fabrication process may result in shade and morphological discrepancies. Previous shade selection systems have not been adequate communication tools and have failed to address the range of colors exhibited by the natural dentition.^{22,25} This article describes the use of a recently developed shade selection system (3-D Master, Vident, Brea, CA) for the accurate communication of desired restoration color and morphology. A simplified technique for the fabrication of aesthetic metalceramic and all-ceramic restorations is also presented.

Shade Communication

The recording and communication of existing tooth shades has been compromised by several factors. Principally, existing shade guides did not address the range of color exhibited by the natural dentition, and no systematic arrangement of color was available.^{22,25} It was clearly necessary to apply color science to the process of shade selection, and to develop appropriate shade-taking systems and matching porcelains. Following significant research of innate tooth color, a shade system has been developed to address the complete range of natural tooth shades within the three dimensions of the color space. The system is arranged first around the selection of value, which is often considered the most important optical parameter. The differences of value among the five levels are exactly equal within the color space. The next step is to determine chroma from the five existing levels, which are equidistant from each other within the color space. The final step is to select the specific hue. Spectrophotometric analysis has demonstrated that the natural dentition exists in a very small hue range (ie, red, orange, yellow).²⁴ The middle range of natural teeth is represented by an orange hue, which becomes increasingly red or yellow as the hue varies from the mean. Based on color science, the process of shade matching has become systematized.

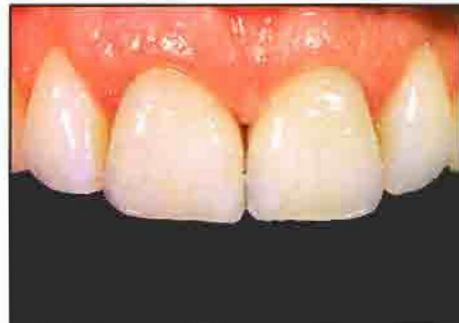

Figure 2. Postoperative facial view of all-ceramic (In-Ceram Spinell, Vident, Brea, CA) crowns used with the shade system to replace teeth #8 and #9.

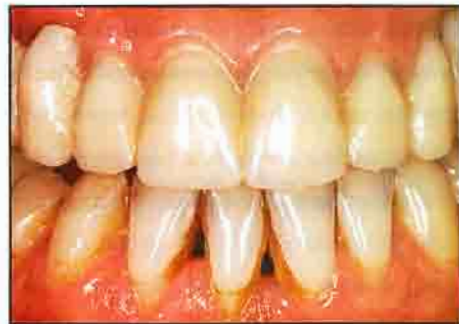

Figure 3. Provisional restoration of the desired form and value.

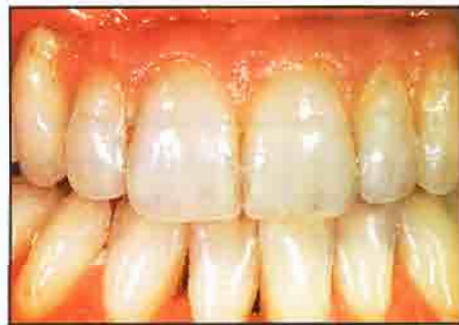

Figure 4. Completed 12-unit fixed partial denture following the design of the provisional restoration (with artistic interpretations).

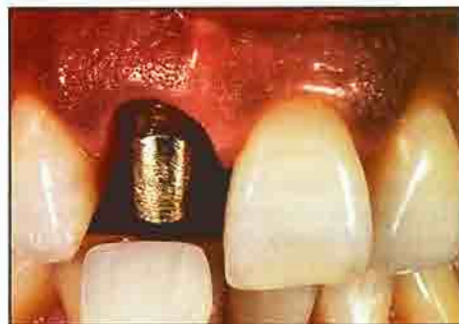

Figure 5. Prepared maxillary incisor (#8) with severe discolorations.

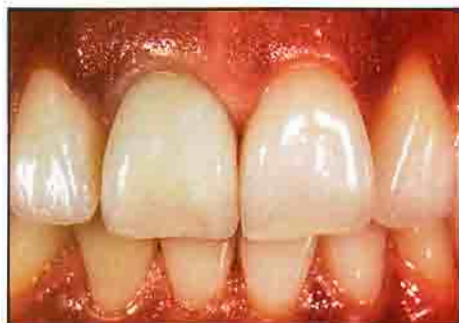

Figure 6. Using the custom shade guide, it was determined that the value was too low. This was attributed to color bleeding through the tooth.

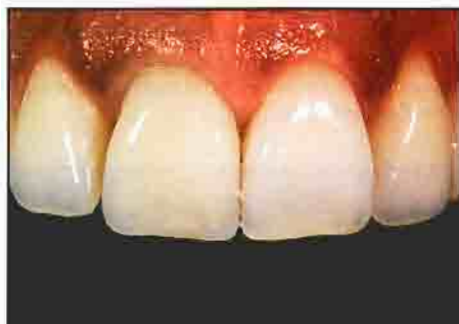

Figure 7. The cemented all-ceramic crown demonstrates a closer value match than that obtained from the custom shade crown.

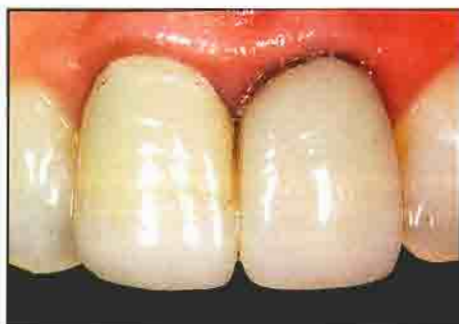

Figure 8. Preoperative view of a maxillary crown restoration that exhibits severely discolored preparations.

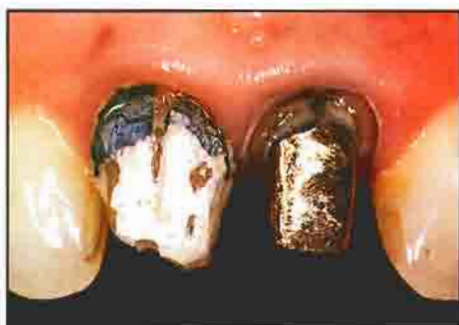

Figure 9. Facial view following removal of the defective crown restorations demonstrates the dark color of the preparations.

Once the value level is selected, the level of chroma is determined. While the modification of chroma level has historically compromised the value, this system has five different chroma levels and three different hues within the value groups. Since it is possible to increase or decrease chroma and change the hue without changing the value, this feature significantly aids in matching prosthetic restorations to natural teeth. The final step is hue selection. Proper hue match is initially assessed relative to the tooth (Figure 1). Specific characteristics (ie, crack lines or decalcifications) are recorded by a drawing or high-quality photography and incorporated in the shade evaluation for fabrication of the definitive restorations (Figure 2).

While provisional restorations have been sparingly used to communicate form, an often overlooked benefit of these materials is the communication of color. Provisional materials that closely approximate the shade guide and accompanying porcelain systems would help address shade issues, allowing intraoral evaluation of the existing dentition during provisionalization.

A new provisional material (Zeta, Vident, Brea, CA) that matches the 3-D Master shade system and its corresponding porcelains has been recently introduced. The material is a cold-cure methylmethacrylate that can be utilized for direct and indirect techniques. Provisional restorations are fabricated in the conventional manner and placed on the prepared teeth to evaluate shade and form (Figure 3). Alterations can be accomplished at the provisional stage to minimize the need for expensive laboratory remakes (Figure 4).

The Custom Shade Guide

In certain situations (eg, teeth with significant polychromatism or translucency), the intraoral try-in of a custom-made shade guide is the only way to precisely match the adjacent dentition. The shade-matching process is initiated as aforementioned with the fabrication of a provisional restoration in the desired base shade; schematic drawings and photographs of the individual nuances are subsequently noted. A restoration that incorporates the different levels of value, chroma, and translucency in the layered ceramic buildup is then fabricated. Special effects (eg, crack lines, decalcifications, and intense incisal effects)

are not necessary at this stage. The objective is to fabricate a restoration with minimal effort that will be used to facilitate the process of shade matching.

Despite the diligent efforts of the restorative team, failure to achieve an accurate shade match between the restoration and the existing dentition is frequently revealed upon try-in. Consequently, it is advantageous to schedule an appointment for a shade try-in to verify the aesthetic expectations of the patient (Figures 5 and 6). The author elects to fabricate two identical sets of provisional restorations: the first is used as a diagnostic tool, the second for cementation. Once the shade is verified, the first provisional restoration is returned to the laboratory as a visual aid for the completion of the definitive restorations. An in-situ photograph can document any discrepancy between the cemented restorations and the natural dentition. The slides are returned to the ceramist in order to complete the modifications for the final porcelain layering. If the shade requires significant modification, the custom guide restoration can be stripped and refabricated; the patient can be rescheduled for shade verification. While this process may appear elaborate, the author has found this to be a time-efficient process. Once the patient is scheduled for final cementation, it is a simple matter to place the custom shade restoration to demonstrate to the patient that the shade or shape of the definitive restorations match the approved shade restoration (Figure 7).

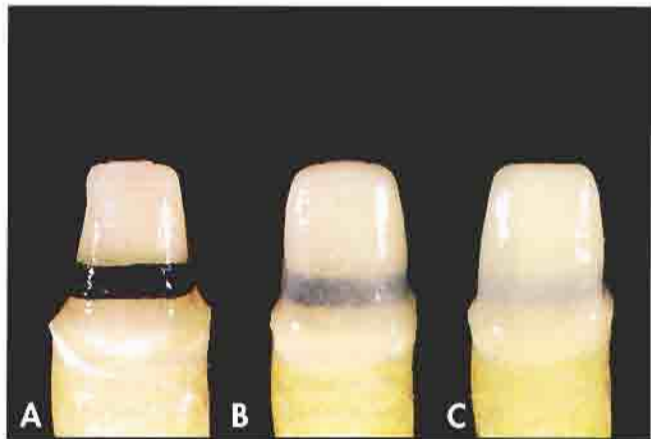


Figure 11A. The core (In-Ceram Spinell, Vident, Brea, CA) prior to vacuum treatment. 11B. The vacuum-infiltrated core is too translucent. 11C. The core with air infiltration is more opaque and effectively masks the dark substrate.

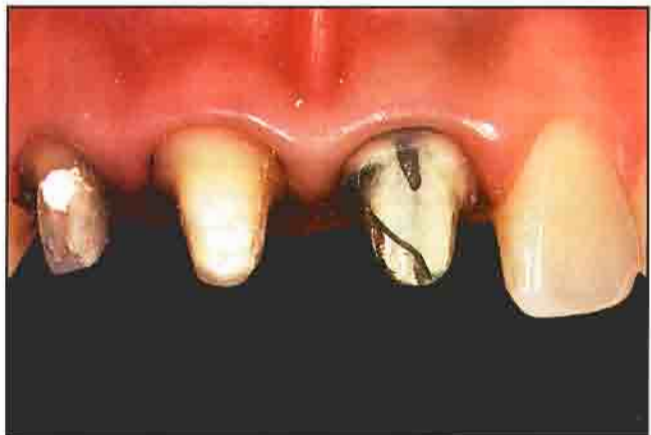

Figure 12. Facial view of patient with normal colored and severely discolored substrates following crown removal.

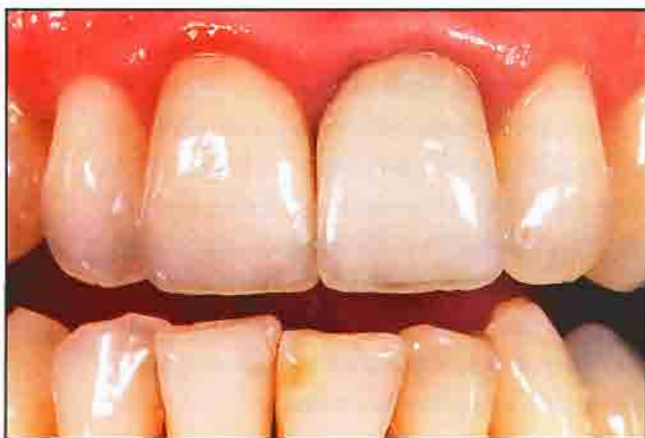

Figure 10. Even when utilizing a porcelain with a higher value, tooth #9 is still too low in value in the gingival third. This is one limitation of highly translucent all-ceramic cores.

Influence of the Underlying Tooth Structure

One of the greatest challenges in anterior aesthetics is the effective restoration of discolored substrates (Figures 8 through 10). Full-coverage and veneer restorations are often placed on discolored teeth, which can be caused by microleakage, sclerotic dentin, metal restorations, posts, and tetracycline staining. While considerable emphasis has been placed on the use of metal-free restorations in the anterior region, this modality often results in increased translucency at the site. The principal concern involving the use of all-ceramic crown techniques remains the inability to mask dark substrates without causing an overly opaque appearance. Early all-ceramic core

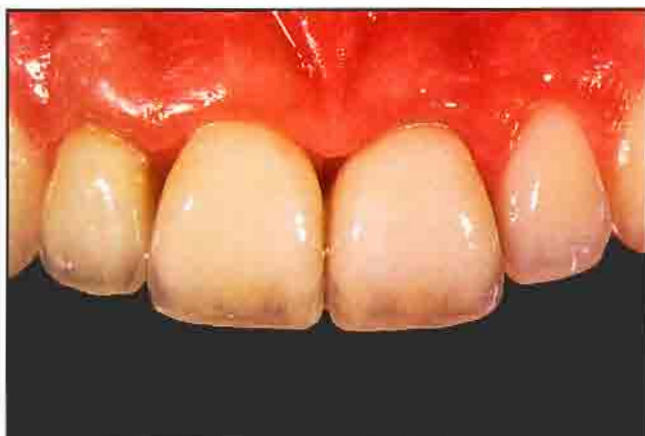

Figure 13. Postoperative view of the patient following alteration of the core translucency. The discolored preparations have been effectively masked.

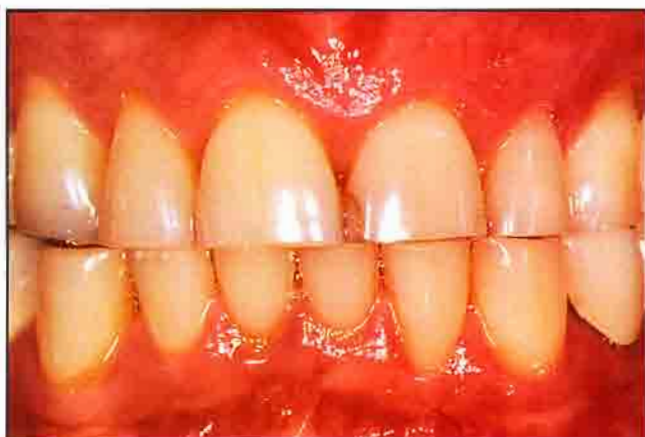

Figure 14. Preoperative facial view of a patient who presented for full-mouth restorations. Note the incisal edge wear and compromised aesthetics.

systems were too opaque and resulted in definitive restorations that did not exceed the current metal-ceramic systems. Recent cast-glass or pressed-glass systems are often too translucent to effectively treat discolored teeth. A significant development would be the ability to alter the translucency of the core to differentially mask the existing clinical situation.

The author discovered that it was possible to alter the translucency of several all-ceramic cores by differentially pulling vacuum during the glass infiltration process. The recommendation for the infiltration of In-Ceram Alumina was an air environment that resulted in a core that was 20% translucent in a segment of 1 mm thickness.²⁶

A vacuum environment is recommended for the infiltration of In-Ceram Spinell, which results in a core that is twice as translucent as In-Ceram Alumina. When In-Ceram Spinell is infiltrated in air, the opacity of the resultant core is significantly increased. Clinical trial and error has indicated that even the most severe discolorations can be masked with air-infiltrated In-Ceram Spinell and brightening porcelains (Luminaries, Vident, Brea, CA) (Figure 11).¹⁴ When utilized properly in dental porcelain, the high fluorescence of these materials tends to instill an iridescent effect that can be used to brighten dark teeth without negatively affecting the translucency.

While In-Ceram Alumina (Vident, Brea, CA) has adequate physical properties for use in single-tooth posterior applications, the relative opacity can create an unaesthetic result in the anterior region. Glass infiltration of In-Ceram Alumina in a vacuum environment produced a core with significantly improved translucency. The translucency of vacuum-infiltrated Alumina was determined to be slightly less than air-infiltrated Spinell (Figures 12 and 13).

In order to enhance the aesthetic potential of the system, the author determined that by cutting back the facial aspect of the core for a porcelain butt margin, a highly translucent material could be fired in this region. Once the restoration was in place, the marginal area was indistinguishable from the existing tooth structure due to the "chameleon effect."²⁷

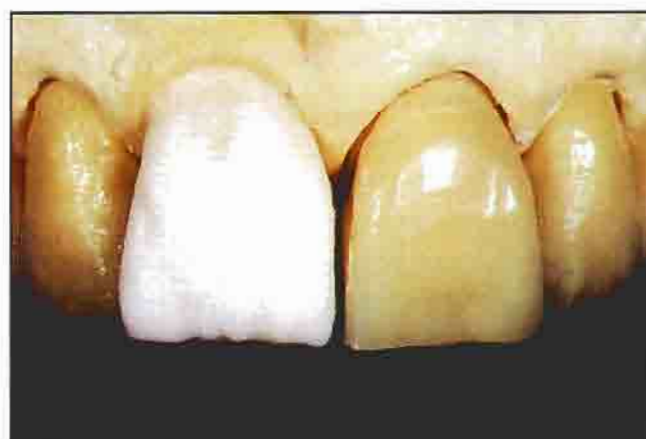

Figure 15. Provisional restorations were used to control form during the porcelain buildup.

Communication of Form and Texture

Significant time and effort are unnecessarily expended when a multilayered restoration is returned following try-in due to form alterations performed by the clinician. The use of a provisional restoration is an effective means of communicating proper form, and ideally should be contoured within 0.2 mm of the desired restoration. Once it has been placed intraorally, the patient can approve the form and color of the definitive restoration. This information can be transferred to the laboratory via a study cast of the provisional restorations.

Again, the use of two sets of provisional restorations is a significant improvement over the previous techniques, since it provides the ceramist with a three-dimensional model of the desired final restoration that can be placed on the working dies. The ceramist can use the provisional restorations to recreate the form, length, labial contours, and embrasure form of the definitive restorations. (Figures 14 through 16).

Porcelain Layering Techniques

Lateral Segmental Layering Techniques

While various techniques have been espoused for layering dental porcelain, most involve sophisticated placement of the various powders, which are built to full contour and fired. The most prevalent of these techniques is the lateral segmental buildup technique developed by Geller.²¹ This technique uses the incremental layering of internal chromas and color modifiers for the dentin portion and laterally placed segments (gingivally/incisally arranged) of different translucencies for the enamel portions. Mastery of this technique requires meticulous placement of each layer and extensive experience with the material to properly assess shrinkage upon firing. If shrinkage is not rigorously controlled, then the desired color effects cannot be achieved. It is also easy to unintentionally mix the individual layers while building; furthermore, the individual layering cannot be viewed until firing.

Internal Live Stain Technique

The internal live stain technique developed by Aoshima allows a greater degree of control than does the Geller technique.¹⁷ The first layer of porcelains are the internal

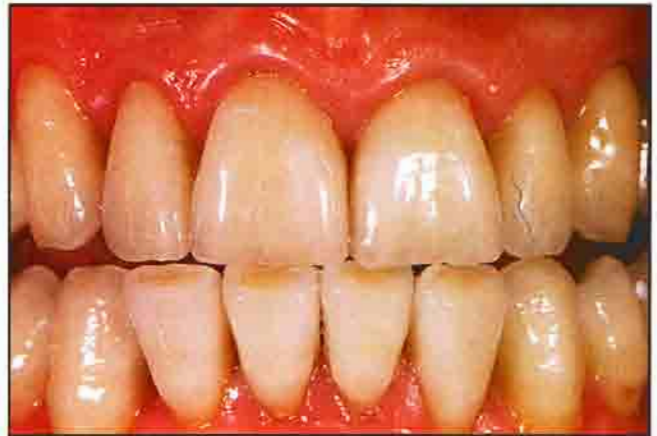

Figure 16. Postoperative view of the definitive restorations. Note the enhanced aesthetics achieved through the use of the provisional shade guides.

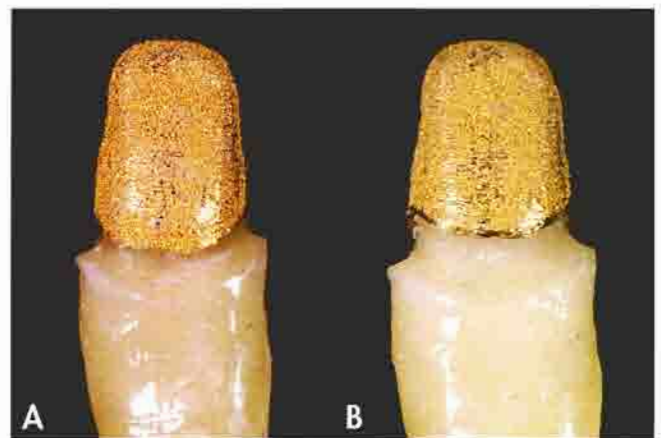


Figure 17A. View of a coping with shadowing at the margin. 17B. The coping with greater cutback demonstrates less shadowing at the marginal area.




Figure 18A. The effect powders under reflected light. 18B. Under transilluminated light, the powders on the reduced coping have optical properties similar to that of the natural tooth. 18C. The powders also exhibit similar fluorescence to the natural dentition.

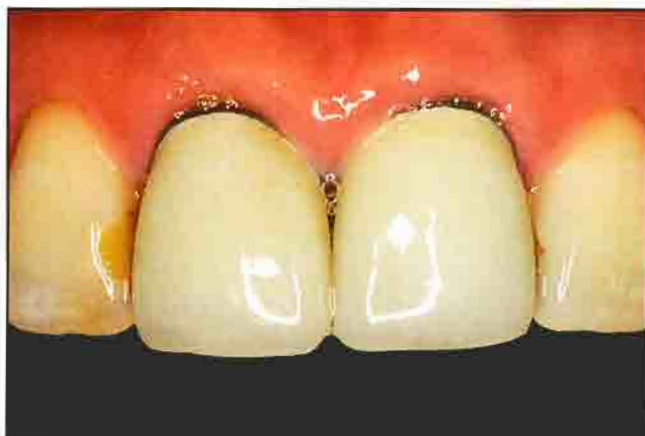

Figure 19. Preoperative view of the patient. Note the compromised aesthetics present at the margin.

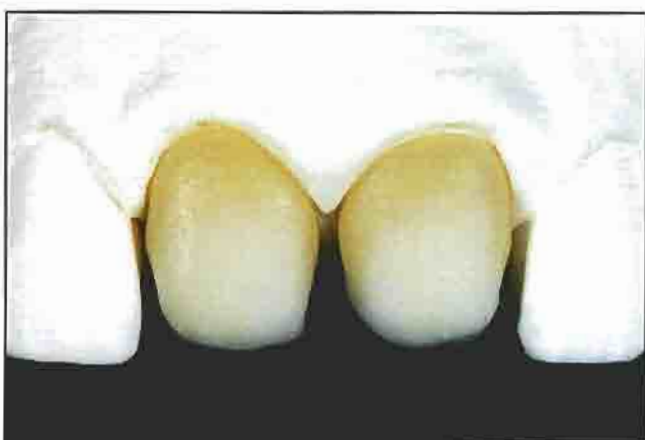

Figure 20. Facial view of the built-up and fired effect powders (Luminaries, Vident, Brea, CA) used as margin materials.

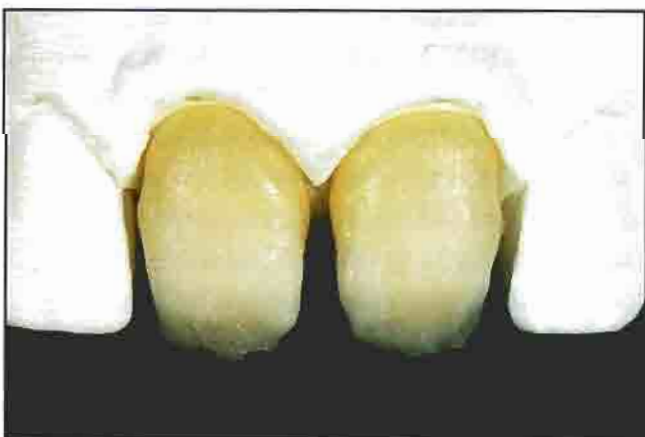

Figure 21. The opacious dentins were subsequently built up and fired. Necessary adjustments may be performed prior to the next phase of the buildup.

structures of the opacious dentin and dentin layers. Incisal framing is subsequently performed, whereby the dentin layer is cut back and incisal or translucent powders are utilized to extend the incisal edge. This in effect becomes the lingual enamel wall; the ceramic layer is then fired without placing a surface enamel layer. Internal "live" stains (Noritake, Secaucus, NJ) are applied over the surface to create mamelons, crack lines, and other desired color effects. Once this layer is fired, enamel and translucent powders are built over the surface and fired, and the crown is contoured and finished in the conventional manner. Utilizing this technique, the opacious dentin and incisal framing layers are subject to the same complications of controlled shrinkage as a full-contour layering technique.

The Skeleton Buildup Technique

This procedure is a compilation of numerous techniques that have been divided into distinct manageable steps. It is so named to create an image of a structure that is built outward from the framework skeleton one layer at a time. These layers are individually completed prior to veneering the enamel surface, thus allowing maximum control of shape and shade. The three-dimensional expression of shade and shape in a porcelain crown requires the exact placement of the internal dentin layers (skeleton) to support the surface enamel layer (skin). Thus, for maximum control, it is best to build each individual layer and then fire it prior to the addition of the subsequent layers. Each layer can be adjusted as necessary by grinding or adding material to each incremental layer prior to proceeding.

Metal Ceramic Framework Design

When fabricating metal ceramic anterior crowns, it is highly recommended to establish a vertically reduced metal framework labially and interproximally.²⁸ The framework is reduced up the axial wall a maximum of 2 mm to allow for translucent porcelains to be used in the marginal region (Figure 17). As long as the margin design is a shoulder with a 90° exit angle, this amount of cutback does not affect the strength of the cemented restoration.²⁹ State-of-the-art metal-ceramic restorations can rival all-ceramic restorations in appearance by using a vertically

reduced metal framework.³⁰ Framework design should allow for maximum thickness of porcelain, within the accepted limits, to minimize susceptibility to fracture. In aesthetic areas for single teeth, frameworks can be safely thinned following casting to 0.15 mm without an increased potential for ceramic fracture,³¹ which can compromise all-ceramic frameworks. Once opaquing has been completed, fluorescent shoulder porcelain materials are built up and fired (Figure 18).

All-Ceramic Framework Design

Due to the high reported flexural strength of these materials, the recommended core dimension for In-Ceram Alumina and In-Ceram Spinell (Vident, Brea, CA) is 0.5 mm.^{32,33} Flexural strengths from 300 MPa to 600 MPa have been reported for In-Ceram Alumina, with 15 to 40 percent lower strength values reported for In-Ceram Spinell.^{34,35} Based on flexural strength alone, In-Ceram Alumina would be indicated for both anterior and posterior single tooth restorations, and Spinell would be indicated for anterior crowns only. These materials are not used independently as a core; they are veneered with a feldspathic porcelain material of significantly lower strength to achieve the definitive aesthetics. Evaluations of the effects of veneering materials have demonstrated only a minimal reduction in strength for the In-Ceram Alumina material if the core thickness remained at 1 mm.¹⁹ When the core was thinned to 0.5 mm and subsequently veneered with 1 mm of porcelain, the flexural strength of the restorations was reduced

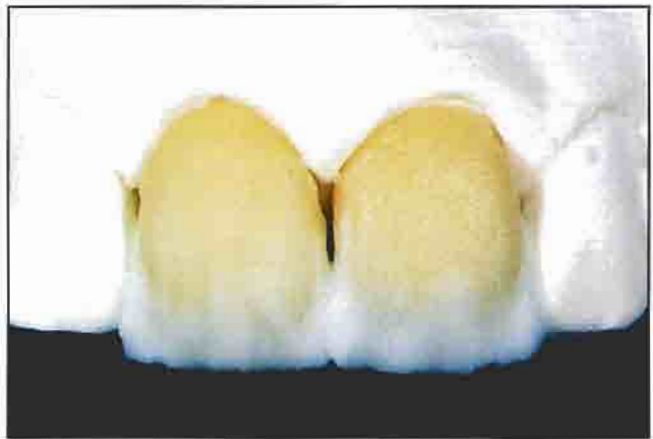


Figure 23. The incisal frame was then built up.

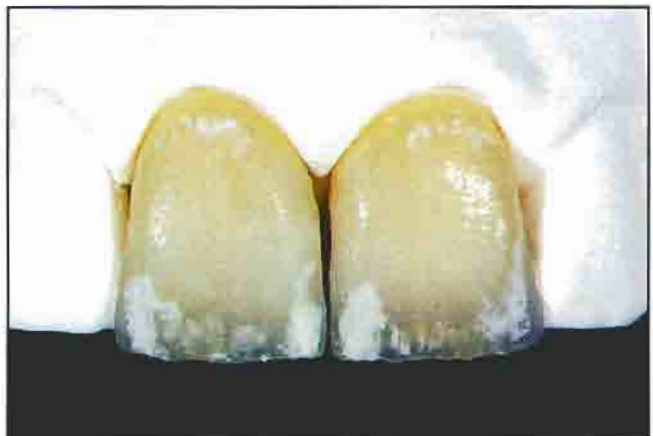

Figure 24. The incisal effects were fired. Note the chalky appearance caused by the low firing.

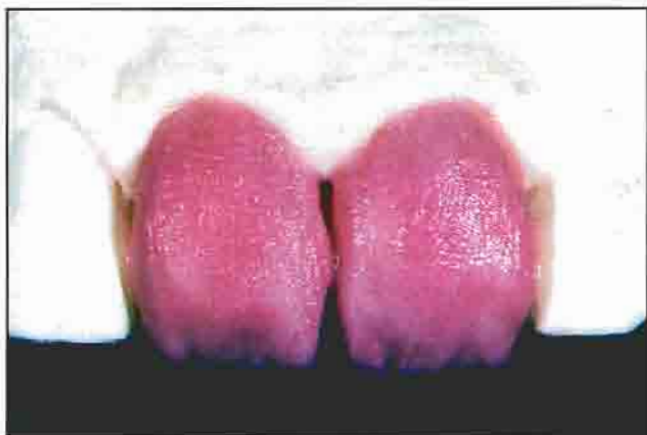

Figure 22. Following the layering of the opacious dentins, the dentin buildup was completed.

to 225 MPa.¹⁶ Although this value would be adequate for incisor and bicuspid regions, it would not be sufficient for molar regions.

Upon review of the author's failures, there were no failed samples with a minimum core dimension of 0.7 mm.^{14,36} All failures originated from an occlusal line angle or an internal flaw evident in the core. It is possible to trap air with the slip-casting technique, creating porosity that can weaken the core. The internal surface of the core must be inspected to reject porosities or flaws. To date, none of the clinical cases fabricated by milling prefabricated In-Ceram Alumina or In-Ceram Spinell monoblocks have failed, regardless of the core dimensions. The benefit of a pre-manufactured block is that there is no residual porosity

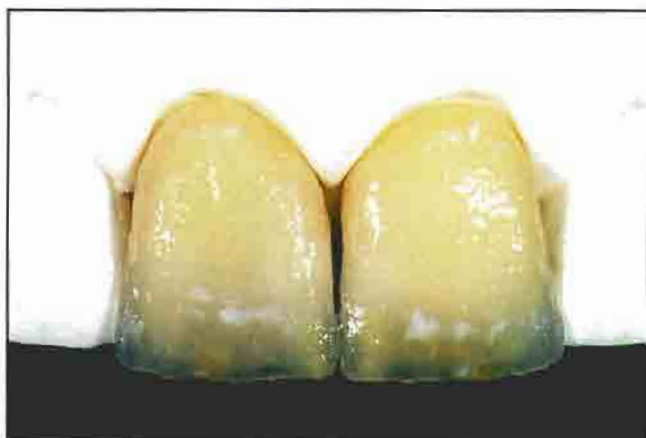

Figure 25. The incisal effects were wet with glycerin to demonstrate the completely sintered color effects.

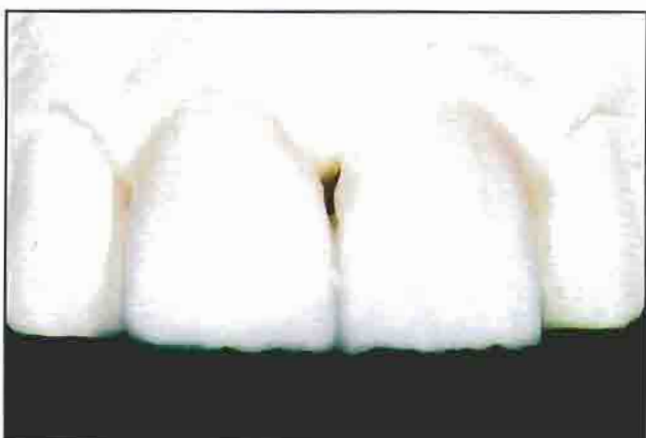


Figure 26. Once the incisal effects were created, the enamel skin (translucent layer) was completed.

in the finished core that could cause failure. Core dimensions in lower stress areas on the facial aspects of the posterior dentition can be thinned to 0.5 mm, as long as the occlusal and palatal areas are thicker than 0.7 mm. Ideally the framework should have a lingual and proximal collar for strength and support of the porcelain. The collar should be 1 mm thick and 2 mm high. For anterior teeth, the core dimensions can be trimmed to 0.3 mm on the facial aspects, as long as the interproximal, palatal, and incisal edge thickness remains at 0.7 mm, and a 1-mm thick collar of the lingual aspect is present.

One of the unique benefits of the In-Ceram system is that the core translucency can be altered during fabrication.¹⁴ This is beneficial in clinical situations where

discolored teeth or teeth with metal posts require restoration. Special effect powders (Luminaries, Vident, Brea, CA) can be placed as a thin wash over the surface of a ceramic core and fired. These powders increase the fluorescence of the definitive restoration, which increases the degree of light reflection. This is particularly beneficial in conditions involving high-value shades or discolorations, as it can raise value without negatively affecting the translucency. The powders can also be utilized as a shoulder material to increase the translucency at the margin area (Figures 19 and 20).

Porcelain Layering

For metal-ceramic and all-ceramic techniques, the remaining steps are identical. Opacious dentins of the desired shade are built up and fired; since it is a simple matter to adjust the fired material, slight overbuilding is preferred (Figure 21). Stains or dentin modifiers can be added to create high chroma effects as necessary. Dentin layers are built up using the base shade dentin in the middle third, with a higher chroma dentin in the gingival third, and a higher value dentin in the incisal third. This creates the subtle contrasts that are evident in natural teeth. Again, it is best to slightly overbuild the dentins, which can be adjusted after firing (Figure 22).

Once the internal structure (skeleton) of the opacious dentins and dentin porcelains have been fired, it is easier to control the position and dimensions of the enamel materials. The lingual wall of the incisal edge (incisal frame)

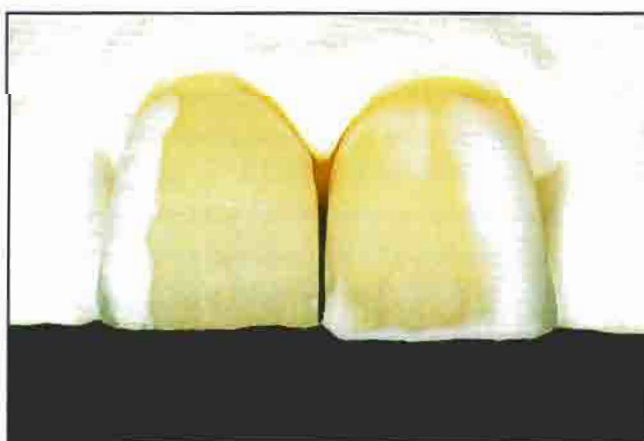


Figure 27. Facial view of the buildup for correction bake, in which an "incisal halo" effect can be created.

is built up with the appropriate enamels and translucent porcelains and subsequently fired. Due to the small volume of porcelain, firing shrinkage is minimal, thus affording maximum positional control of the incisal edge. Slight over- and underbuilding can be adjusted prior to the placement of the next layer (Figure 23).

Mamelon or other internal effects are then created. Special high-chroma porcelains (Intensives, Vident, Brea, CA) or fluorescent stains (Internos, Vident, Brea, CA) are layered on top of the fired dentin to create these effects. These are air-fired to only 800 C° to set them on the surface. Firing to 800 C° will not affect the internal microstructure of the fired dentins and enamels, thus minimizing the devitrifying effect of multiple firings. Since they are incompletely sintered at this point, the applied effect powders appear chalky (Figure 24). Wetting the surface with a glycerin-type liquid alters the refractive index to allow viewing the fired effects (Figure 25). This step can be repeated as necessary until the desired effects are obtained. If the effects are excessive, they are removed prior to proceeding to the next layer. With a full-contour buildup technique, effects cannot be viewed until sintering is completed.

The final step in the process is the placement of the enamel/translucent layer. Due to the control of the internal layers (skeleton), the enamel/translucent layer (skin) is easily manipulated. Various translucent powders can be built up incrementally as in the lateral segmental technique (Figure 26). Overbuilding is preferred to allow slight contouring of the porcelain after firing, rather than a second addition of translucent porcelains to complete contour. It is critical to prevent devitrification by minimizing the number of firing cycles of the translucent porcelains. Devitrification is caused by crystal growth within the porcelain on multiple firings and makes the restoration appear cloudy. Materials added to translucent porcelains to create the opalescent effect act as nucleating agents mediating this process. Dentin powders generally do not have opalescent agents added to the material, and devitrification on multiple firings is less common. If an incisal halo effect is desired, it is created by placing a thin bead of a mixture of dentin and enamel porcelain at the incisal edge of the facial translucent layer. Slight corrections of

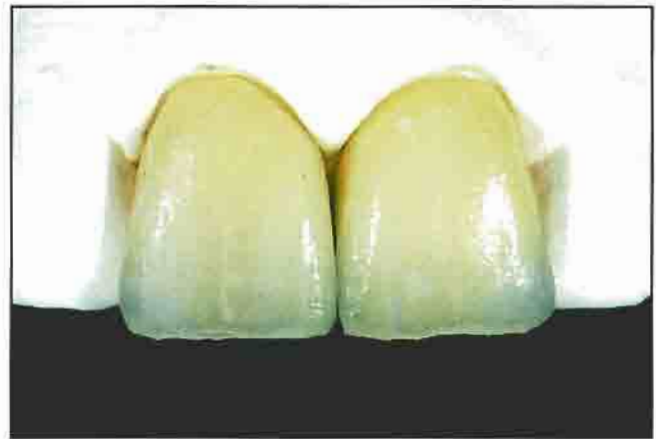

Figure 28. View of the definitive all-ceramic restorations following correction firing and prior to definitive contouring and glazing.

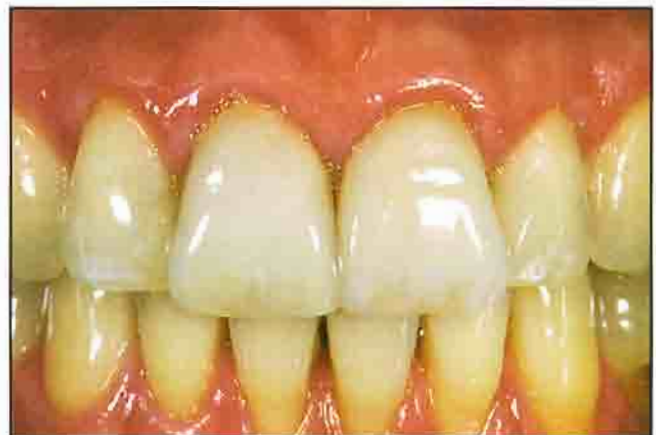

Figure 29. Postoperative view of the patient. Note the optimal contour and aesthetics achieved with this buildup technique.

form can also be completed by the addition of small amounts of translucent porcelains, which are then fired to complete the ceramic layering (Figures 27 and 28). Prior to glazing, the enamel/translucent layer is fired a maximum of two times.

Contouring and Glazing

Contouring and surface texturing are completed as necessary using diamond burs and stones. It is important to note that the natural dentition exhibit a degree of surface texture, even in the teeth of geriatric patients. Proper contour and texture are prerequisites for the achievement of natural-looking restorations. There is currently discussion regarding the need to autoglaze or overglaze the restoration.¹⁷

It is believed that autoglaized porcelain and polishing enables natural-looking restorations to be accomplished.³⁷ Due to development of a compressive layer on the overglazed surface, these restorations exhibit significantly enhanced flexural strengths as compared to autoglaized porcelain.³⁷ Once overglazed porcelain is polished, this technique cannot be distinguished from the overglazed technique (Figure 29).

Conclusion

A technique has been presented that allows systematic control of the shade and shape of metal-ceramic and all-ceramic restorations. While this layering process may appear time-intensive, the time spent building porcelain is exactly the same as that utilized by other techniques; the only difference is the duration of firing. The benefits of this technique are complete control of each step in the porcelain stratification procedure and the ability to view and adjust each layer incrementally.

Due to poor matching of existing shade guides to the color ranges of natural teeth, shade communication has historically been problematic. A new shade-matching system (3-D Master, Vident, Brea, CA) has been developed based on extensive study of natural teeth. The system uses color science to create a logical arrangement and spacing within the color space of natural teeth, which greatly facilitates the shade-matching and communication process.

Acknowledgment

The author mentions his gratitude to Joe Wiesz, CDT, and Chris Lawthrop, CDT, for the fabrication of the Captek copings presented in the article. The clinical and all-ceramic procedures were performed by the author.

References

- Kelly JP, Nishimura I, Campbell SD. Ceramics in dentistry: Historical roots and current perspectives. *J Prosthet Dent* 1996;75(1):18-32.
- Anusavice KJ. Recent developments in restorative dental ceramics. *J Am Dent Assoc* 1993;124:71-84.
- 1990 Survey of dental restorations. In: Survey of Dental Services. American Dental Association Survey Center, Carol Stream, IL: 1990.
- Giordano RA. Dental ceramic restorative systems. *Compend Cont Educ Dent* 1996;17(8):779-794.
- Shoher I, Whiteman A. Captek: A new capillary casting technology for ceramometal restorations. *Quint Dent Technol* 1995;18:9-20.
- Meier B, Komma O, Kempf B, et al. A new metal-ceramic system: Some aspects of materials technology. *Dent Lab* 1993;9:1-6.
- Kappert HF. Modern metal-ceramic systems with Omega 900. *Zahnärztl Mitt* 1996;18:1-8.
- McLaren EA. Current state of the art in metal-ceramic technology. *Pract Periodont Aesthet Dent* 1998. In Press.
- McLaren EA, Sorensen JA. High strength alumina crown and bridge substructures generated using copy milling technology. *Quint Dent Technol* 1995;18:31-38.
- McLaren JW. New dental ceramics and esthetics. *J Esthetic Dent* 1995;7(4):141-149.
- McLaren EA. Luminescent veneers. *J Esthet Dent* 1997;9(1):3-12.
- Pröbster L. Survival rate of In-Ceram restorations. *Int J Prosthodont* 1993;6(3):259-263.
- Scotti R, Cotapano S, D'Elia A. A clinical evaluation of In-Ceram crowns. *Int J Prosthodont* 1995;8(4):320-323.
- McLaren EA. All-Ceramic alternatives to conventional metal restorations. *Compend Contin Educ Dent* 1998;19:307-325.
- Sorensen JA, Kang SK, Torres TJ, Knöde H. In-Ceram fixed partial dentures: Three-year clinical trial results. *J Calif Dent Assoc* 1998;26:207-214.
- Sieber C. Variations in light and conduction and light intensity. *Quint Dent Technol* 1994;17:95-101.
- Aoshima H. Aesthetic all-ceramic restorations: The internal live stain technique. *Pract Periodont Aesthet Dent* 1997;9(8):861-868.
- Tanaka A. Fabrication of a bridge using the Sunrise Metal Ceramics System. *Quint Dent Technol* 1989;13:87-94.
- Kuwata M. Anatomical shading technique utilizing the Synspray Porcelain System. *Quint Dent Technol* 1997;20:125-135.
- Yamashita T, Katayama T, Neyret S. Using the Internal Live Stain Technique to achieve optimal esthetic results. *Quint Dent Technol* 1993;16:71-78.
- Aiba N. Fabrication of custom-made ceramic restorations using Willi Geller's Technique. *Quint Dent Technol* 1992;15:47-56.
- Preston JD, Bergen SF. *Color Science and Dental Art*. St. Louis, MO: Mosby Books; 1980:31-45.
- Miller LL. Shade selection. *J Esthet Dent* 1994;6(2):47-60.
- Miller LL. Shade matching. *J Esthet Dent* 1993;5(4):143-153.
- Sorensen JA, Torres TJ. Improved color matching of metal-ceramic restorations. Part 1: A systematic method for shade determination. *J Prosthet Dent* 1987;58(2):133-139.
- Ironsides JG. Light transmission of a ceramic core material used in fixed prosthodontics. *Quint Dent Technol* 1993;16:103-106.
- Materdomini D, Friedman MJ. The contact lens effect: Enhancing porcelain veneer esthetics. *J Esthet Dent* 1995;7(3):99-103.
- Meyenberg KH, Imoberdorf M. The aesthetic challenges of single tooth replacement: A comparison of treatment alternatives. *Pract Periodont Aesthet Dent* 1997;9(7):727-735.
- Lehner CR, Männchen R, Schärer P. Variable reduced metal support for collarless metal ceramic crowns: A new model for strength evaluation. *Int J Prosthodont* 1995;8(4):337-345.
- Winter R. Achieving esthetic ceramic restorations. *J Calif Dent Assoc* 1990;18:21-24.
- McLaren JW, Sced IR. Reinforcement of aluminous dental porcelain crowns using a platinum alloy preformed coping technique. *Br Dent J* 1987;163(11):347-352.
- Sadoun M. All-Ceramic bridges with slip casting technique. Presented at the 7th International Symposium of Ceramics, Paris, France: 1988.
- Claus H. Vita In-Ceram, a new procedure for preparation of oxide-ceramic crown and bridge framework. *Quintessenz Zahntech* 1990;16(1):35-46.
- Seghi RR, Daher T, Caputo A. Relative flexural strength of dental restorative ceramics. *Dent Mat* 1990;6(3):181-184.
- Seghi RR, Sorensen JA. Relative flexural strength of six new ceramic materials. *Int J Prosthodont* 1995;8(3):239-246.
- McLaren EA, White SN. Clinical performance of In-Ceram crowns and fixed partial dentures in a private practice followed for up to 7 years. In Press.
- Giordano R, Cima M, Pober R. Effect of surface finish on the flexural strength of feldspathic and aluminous dental ceramics. *Int J Prosthodont* 1995;8(4):311-319.